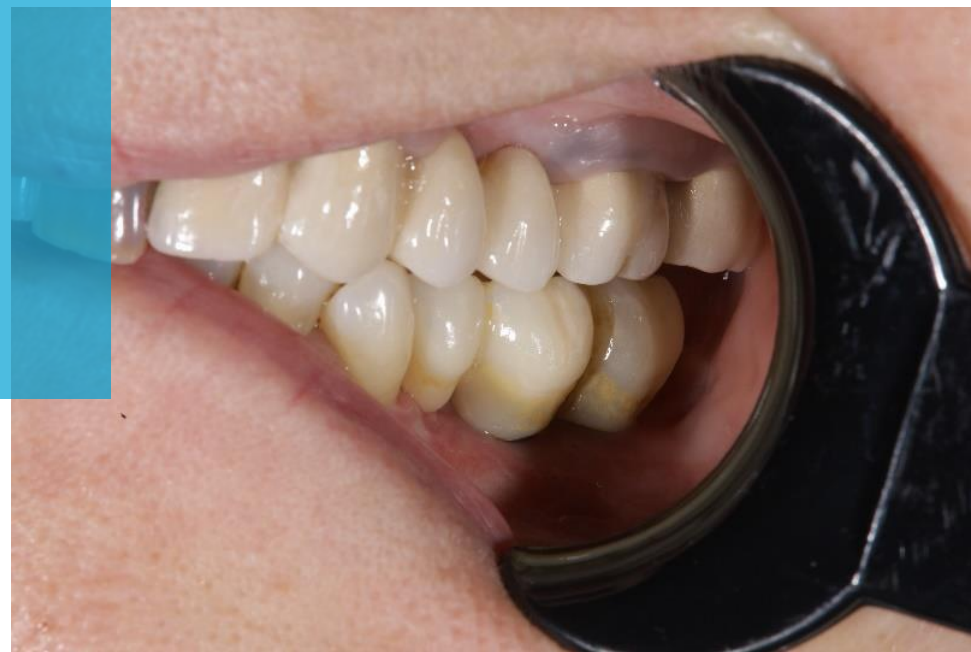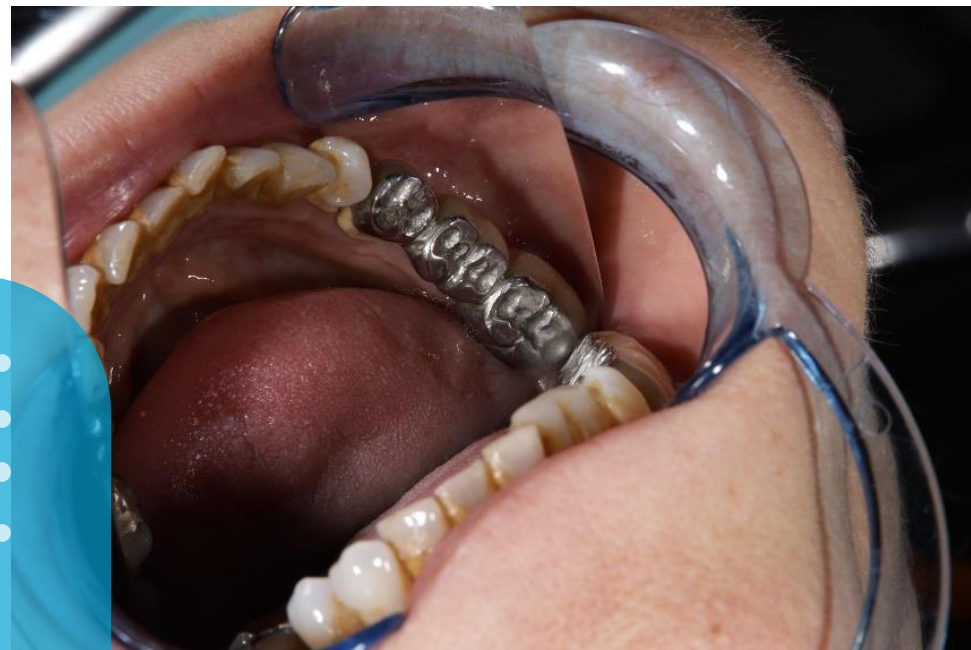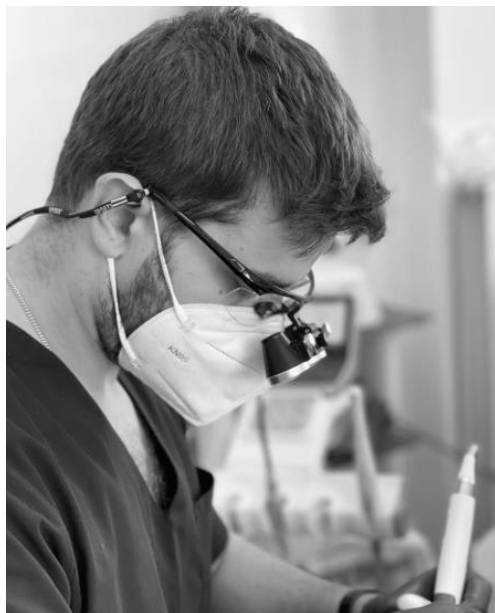


Cas clinique

Implants DESS® Conical BLT posés après extraction d'un bridge métallique

Le Dr Nikolaos S. Karatzeas présente un cas implantaire, de la
dépose d'un bridge fixe jusqu'à la restauration prothétique finale
sur implants.





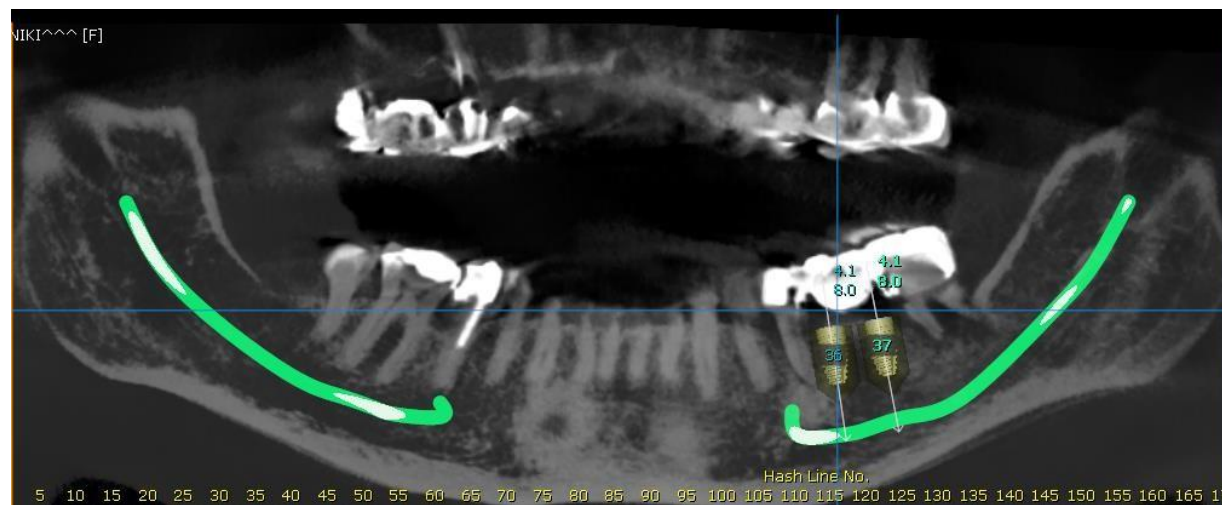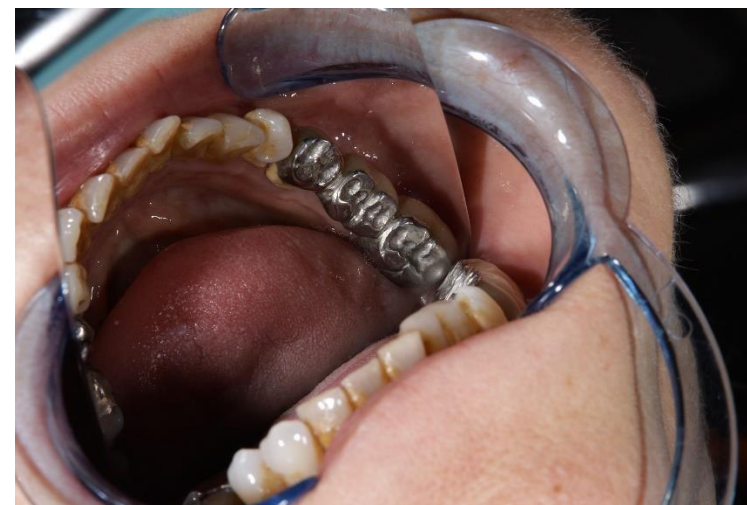Dr. Nikolaos S. Karatzeas

Kalamata (Greece)

CASE PRESENTATION

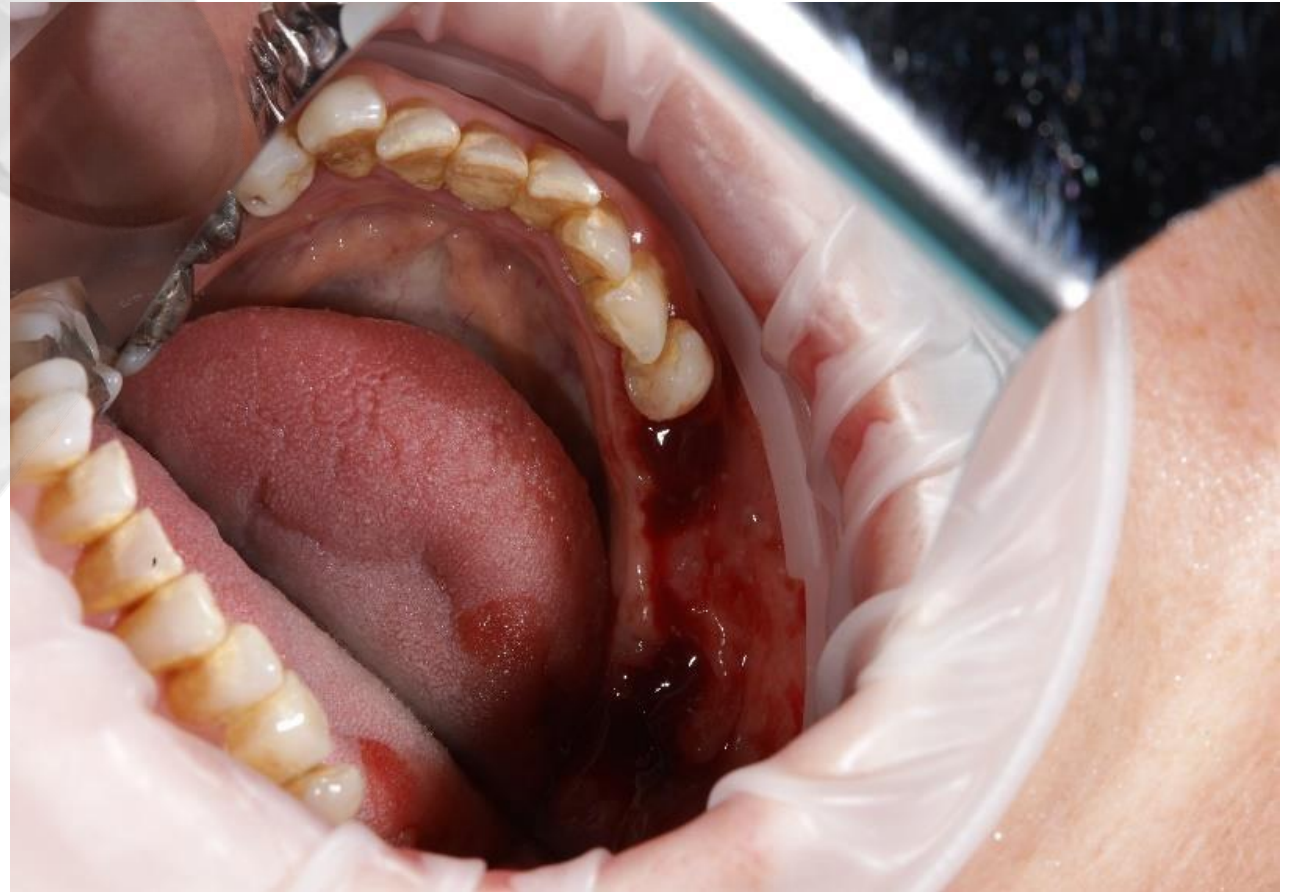
A woman, 70-year-old patient, nonsmoker and no risk factors but with poor oral hygiene, presented to the dental clinic with a failing metal bridge 35 to 37.

After radiographic evaluation, the need for the removal of the bridge was necessary. Patient after through evaluation accepted the treatment plan, extraction the old bridge followed by 2 implants and a new fixed restoration a 3-unit bridge over implants.



Initial situation

Implant placement of post-extraction site, is a very common technique in daily dental practice. If the clinical circumstances are favorable, it is possible to save clinical time by placing the implants at the same day after extraction.

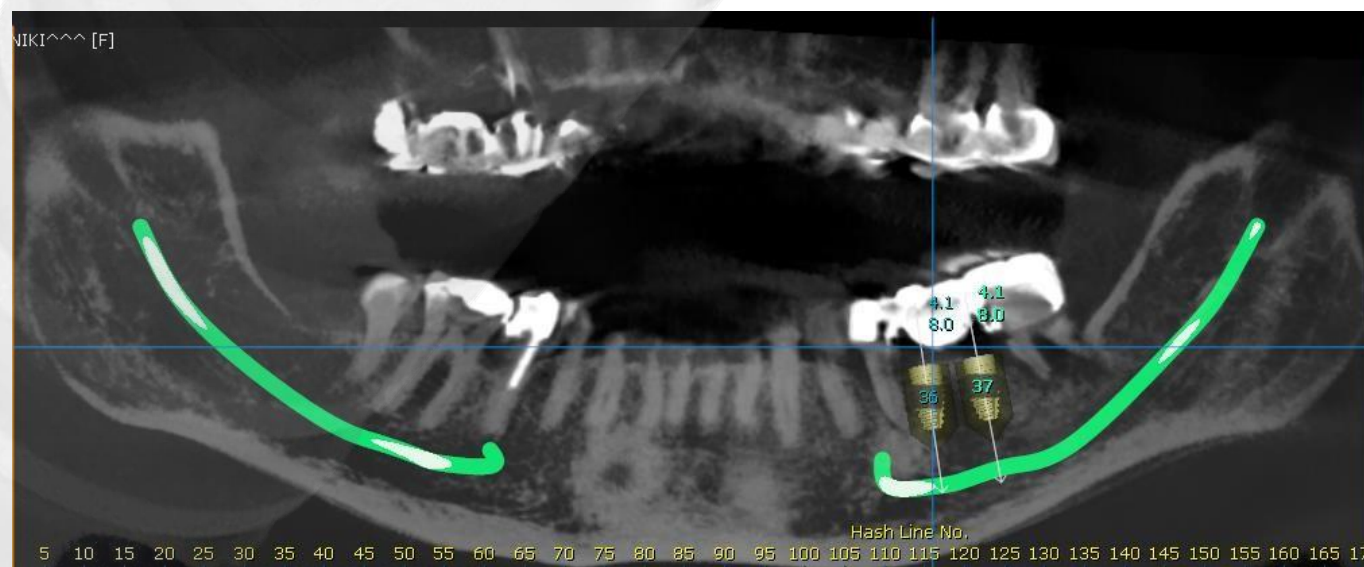


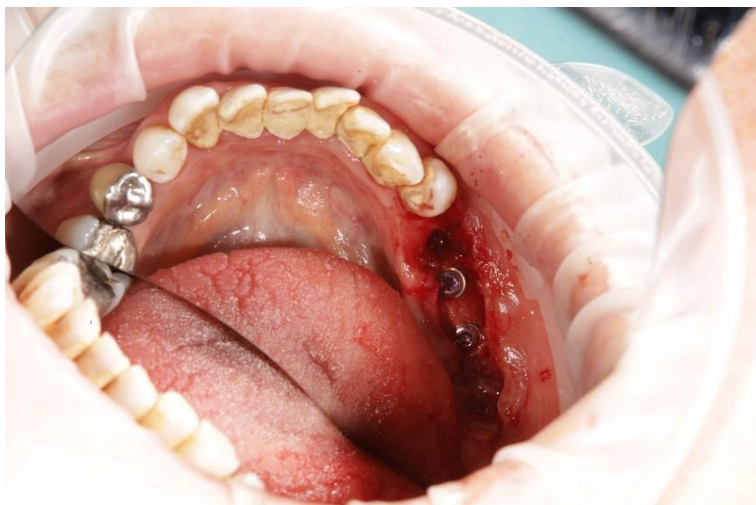
Pre-planning of implant placement is an important step, selecting the appropriate platform and length and in this particular implant case is crucial.

According to CBCT, the implants of choice were *DESS ®Conical BLT implants with 4.1 x 8 mm* platform, as they respect the Golden Ratio of the bone around the implant, as well as the proximity of the IAN nerve (green line).

An assessment was made of placing 4.8 platform implants, but this would compromise the safety guidelines of the treatment plan in the molar area.

Finally, it was planned to place two implants 4.1 x 8mm on position 36 and 37.





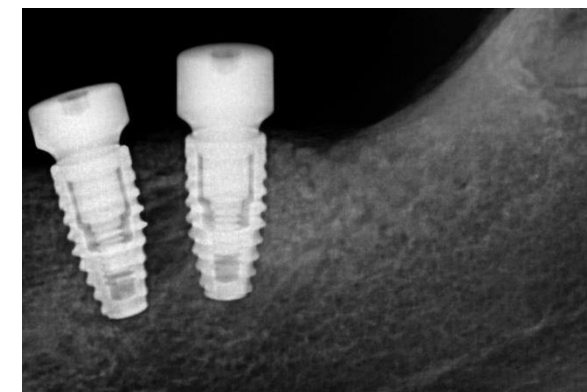
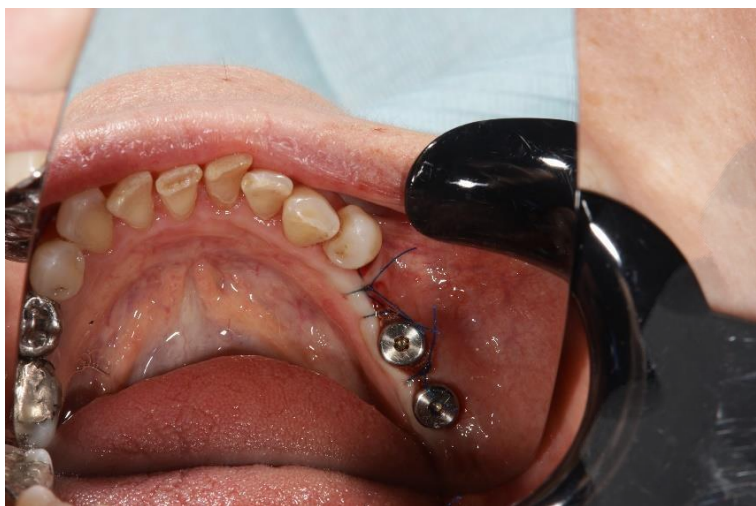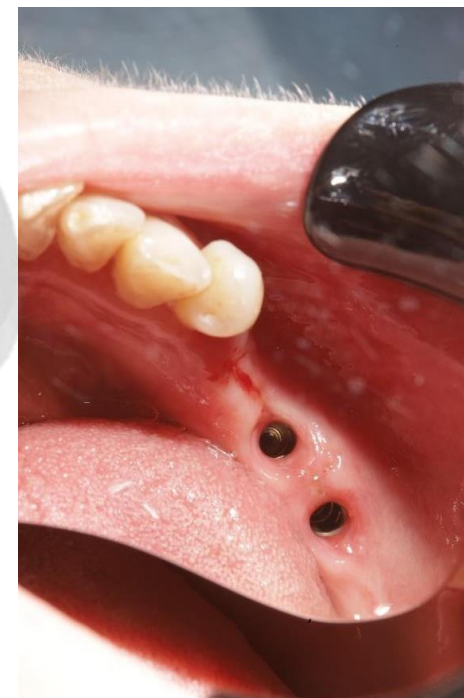
The placement of the *DESS® Conical BLT implants* provided excellent primary stability in the bone.

Dr. Karatzeas avoided placing the implant in extraction sockets and placed it where was sufficient bone. The reason being that the patient is on bisphosphonate therapy due to osteoporosis and has poor oral hygiene.

Dr. Karatzeas tried to make it as uncomplicated as possible to avoid complications.

Planning the placement of an implant in the post-extraction socket will alter the treatment plan, making it necessary to use bone grafts and membranes, lengthening the healing process.

Healing abutments were placed during the 4-month osseointegration period, which allowed a perfect gingiva to be formed when the clinical situation was found to be suitable to start the final prosthetic restoration.





TECHNICAL INFORMATION

- Cold worked Titanium Grade IV
- Same implant platforms and lengths as Straumann® Bone Level®.
- Internal cross connection
- OST by DESS® (Osseointegration Surface Technology) - acid etch and sandblasting treatment. Complies with SLA standards.
- Bone level tapered implant design
- Esterilised by radiation
- CE: Class IIb
- FDA: Class II



FEATURES

- Pure Switch® concept
- Dual function connection: internal conical at 15° with 4 internal grooves that improve stability
- Packaging: PET blister, titanium vial and cardboard box
- Tapered apical and self-cutting design



CLINICAL BENEFITS

- The tapered apical threads and self-cutting design are ideal for soft bone or very soft bone.
- The bone level tapered implant design allows for maximised crestal bone preservation and microgap control.
- All the features combined together provide excellent primary stability.
- Pure Switch®: The implant can be placed with DESS® Surgical Kit or Straumann® Bone Level® Surgical Kit¹ and protocol.
- Cold worked Titanium Grade IV for superior mechanical resistance.



BUSINESS BENEFITS


- Pure Switch®: Lower investment by using Straumann® Bone Level® tools with Conical BLT® implant.
- Zero Waste - consists in recycling and reusing 100% of it's packaging. For every 10 empty packs returned, DESS provides 1 free implant.

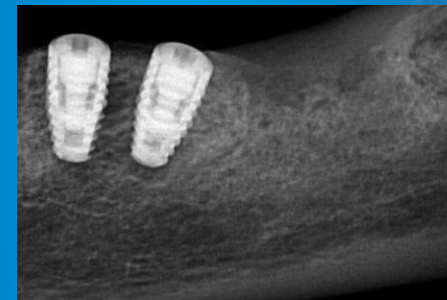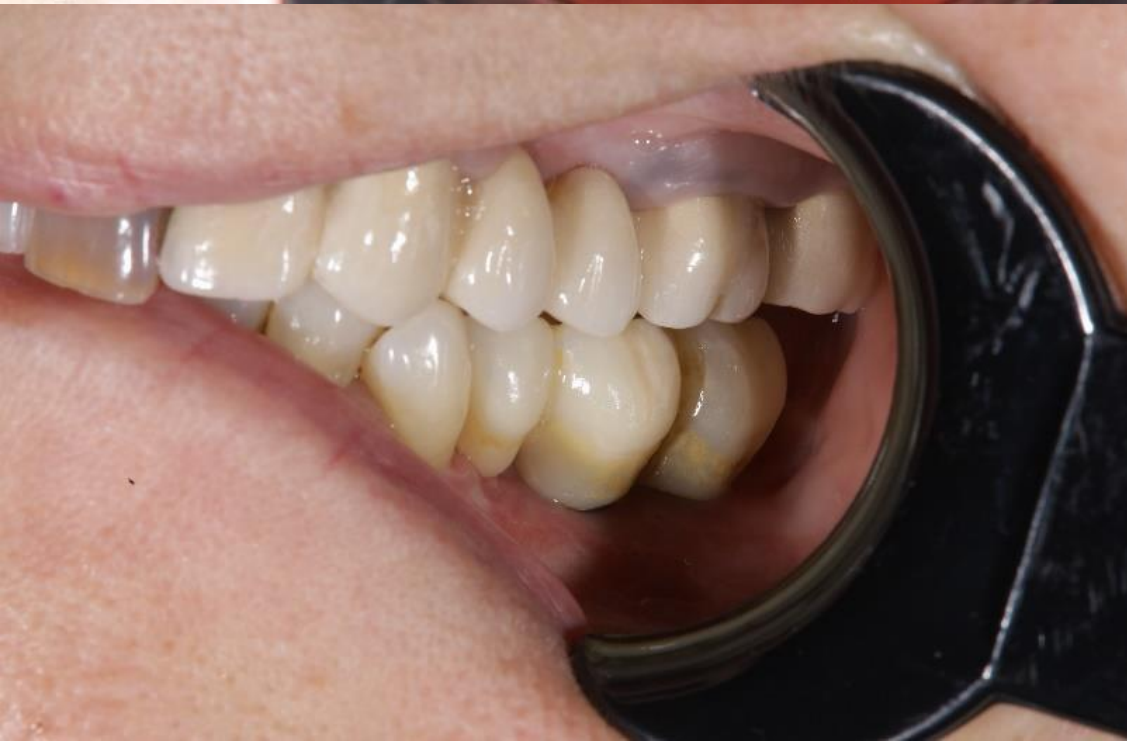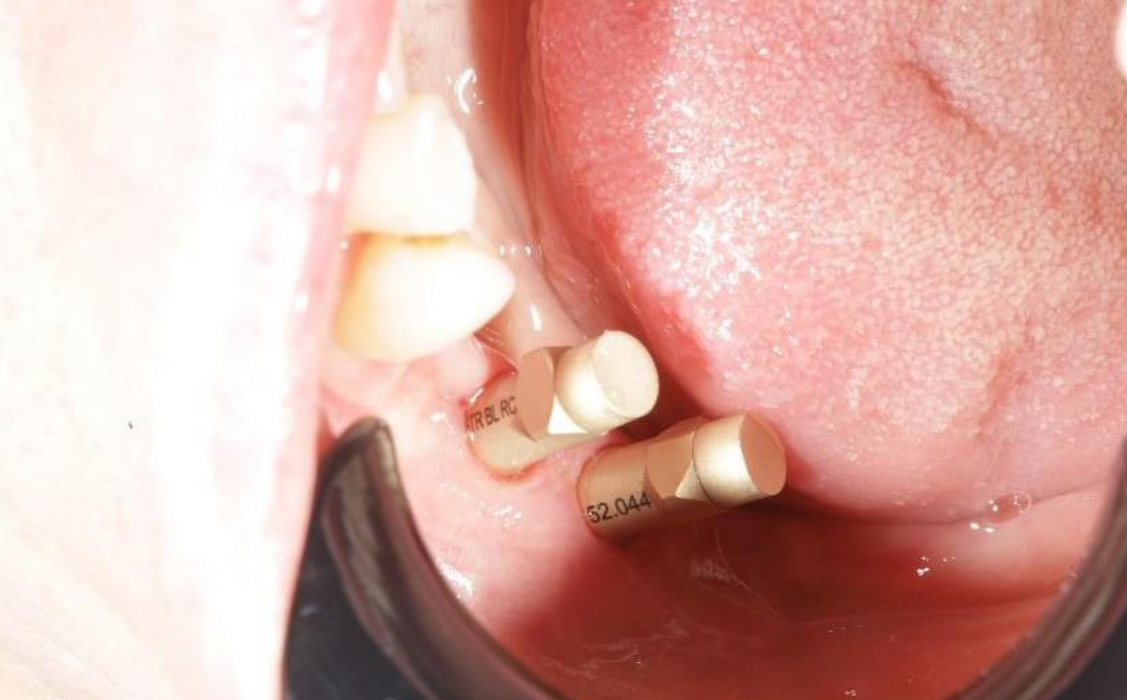¹ It's necessary to buy DESS® implant drivers for each platform and adaptor DTSTTR.

DESS® Conical BLT implant



OSSEOINTEGRATION SURFACE TECH OST by DESS®



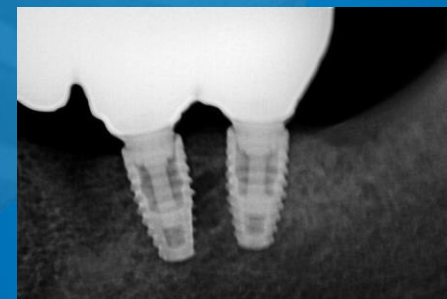

Conclusion

DESS® scan bodies were used for the intraoral scanning.

Dr. Karatzas designed and milled chairside a the 3-unit Zirconia Multilayer screw-retained bridge on DESS®Tibases.

The final result shows how a failed metal bridge could be replaced with a new one over implants, offering the patient a highly satisfactory solution to her unfavorable clinical situation when she visiting Dr. Karatzas Clinic.





Dr. Nikolaos S. Karatzeas

Greece

- University of South Carolina UpState- Bachelor Degree 2009 - 2013
Doctor was enrolled on PreDental Program taking the Prerequisite for dentistry
- Dentistry. Medical University of Sofia 2013 - 2018
- Owner since 2020 Karatzeas Dental Care, in Kalamata (Greece), focusing on Dental Implantology, Aesthetic Dentistry, Digital Dentistry and Periodontology

